

Morphometry of Pterion and its Relation with Middle Meningeal Artery in Dry Human Skulls- A Cross-sectional Study

VEERESH ITAGI¹, NAGARAJ MALLASHETTY², JAYASUDHA KATRALLI³, ICHITHA SHANKAR⁴

ABSTRACT

Introduction: On the side of skull bone in both sides there is a significant area Pterion which acts as a landmark in neurological surgeries. All four bones meet here at this H-shaped sutural junction. Knowledge of various types of pterions and position is important in neurosurgeries, interpretation of radiographs and in forensic medicine.

Aim: To analyse the morphometry of pterion and its relation with nearest branch of Middle Meningeal Artery (MMA) in dry human skulls of Davangere, Karnataka, India.

Materials and Methods: The present cross-sectional study was conducted on 100 adult dry human skull bones, 200 pterions at Shamnur Shivashankarappa Institute of Medical Sciences and Research Centre, Davangere, Karnataka, India for a period of one year October 2017 to September 2018. Murphy's classification

was used for the type of pterion. Mean distance between centre of pterion to different bony landmarks on external as well as internal aspects of skull on both sides was measured. Unpaired t-test was employed to analyse the data. The p-value of <0.05 was taken as statistically significant.

Results: Sphenoparietal 161 (80.5%) type of pterion was found to be the commonest followed by epipteric 20 (10%), stellate 10 (5%) and frontotemporal 9 (4.5%). Mean distance between the pterion and point nearest to branch of MMA was 2.39 mm on the right-side and 2.19 mm on the left-side of the skull with significant difference.

Conclusion: It can be concluded that sphenoparietal type is the commonest type followed by epipteric, stellate and frontotemporal type. No difference was found between right and left-side pterions in type or its relations to bony landmarks.

Keywords: Epipteric, Frontotemporal, Morphology, Sphenoparietal, Stellate, Zygomatic arch

INTRODUCTION

Pterion is a neurosurgical landmark located in temporal fossa. Frontal bone, greater wing of sphenoid, squamous part of temporal bone and parietal bone almost meet at a region forming a H shaped structure- pterion [1]. It is a circular area located at around 4 cm higher to zygomatic arch and 3.5 cm behind the frontozygomatic (FZ) suture. Using cranial suture closure methodology pterion helps in determining age. It relates to the anterolateral fontanelle on neonatal skull and disappears in less than three months after birth [2]. The fontanelles allow shaping of the fetal head while it passes through the birth canal and also help in faster growth of brain in first year of life [3]. Pterion is posterior to the frontal process of the zygomatic bone by a thumb's width and two fingers' breadth superior to the zygomatic arch [1]. Pterion has gained interest by forensic science experts and anthropologists, due to variation in its pattern in different population groups.

Broca classified pterion into three types: sphenoparietal, frontotemporal and stellate [4]. Later Murphy classified into four types [5]. Sphenoparietal: Greater wing of sphenoid and parietal bones are in immediate contact. Frontotemporal: where frontal and temporal bones are in close connection. Stellate: Frontal, parietal, sphenoid, and temporal bones articulate at a single point. EpIPTeric: characterised by presence of small sutural bones between four bones forming pterion.

Genetic and environmental factors can be responsible for skull suture growth and can affect formation of different type of pterion [6]. Structures related to pterion include Broca's motor speech area on the left-side, MMA, anterior pole of insula, the lateral (Sylvian) cerebral sulcus and internal capsule. Pterional keyhole approach is used for surgeries involving Broca's area, sphenoid ridge, in treatment of lesions of optic canal, cerebral aneurysms and tumours such as lipomas, olfactory meningiomas [7-9]. Keyhole surgeries

provide minimal brain retraction, minor tissue injury, shorter duration of surgery and greater cosmetic outcomes. As pterion marks the anterior MMA ramus, pterional fractures can tear the artery leading to subdural hematoma which can further exert pressure on the underlying cerebral cortex leading to complications if untreated. Pterion is also called Sylvian point.

Pterion is used as landmark to read an X-ray. Frontal bone near pterion appears radiolucent and can be mistaken as intracranial pneumocephalus [10]. In cases of traumatic injuries presence of more than one sutural bone is usually confused with fracture of skull in this region of pterion [11]. Understanding of location of pterion helps in identifying sutural asymmetry. These positional definitions with these parameters are obtained only from dried skull bones and possibly serve as appreciated values for the radiologists and surgeons in handling pathologies in this part of cranium. Many similar studies have been conducted in India. Despite its clinical, data of central Karnataka population is still scarce. So the present study was undertaken with objectives to locate and classify pterion, compare with the literature and its relation to nearest branch of MMA in the skull bones of central Karnataka region.

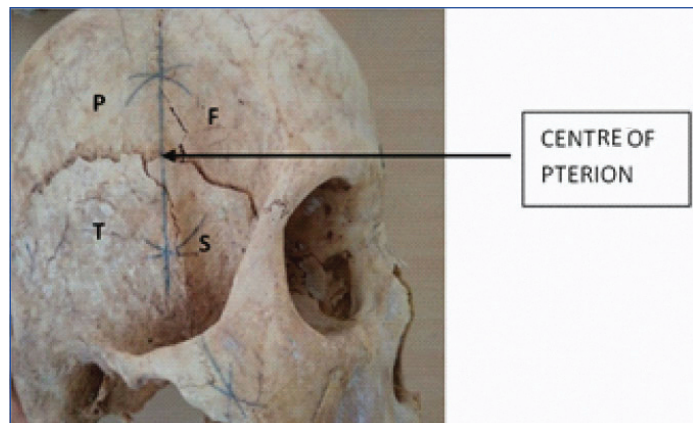
MATERIALS AND METHODS

This cross-sectional study was conducted on 100 adult dried human skull bones of unknown age and gender belonging to Department of Anatomy, Shamnur Shivashankarappa Institute of Medical Sciences and Research centre, Davangere for a period of one year (October 2017 to September 2018). Total of 200 pterions from both sides were included in the study and approved by the Institutional Ethics Committee (IERB No. 188-2018).

Inclusion and Exclusion criteria: Dry and intact skulls were included. Skull bone which were damaged, deformed, have callous formation and unossified bones were excluded from the study.

Type of pterion depending on sutural pattern was determined based on Murphy's classification [5] into sphenoparietal, frontoparietal, stellate and epipteric types on both the left and right-sides of each skull.

A circle was drawn with minimum radius linking the four bones which form the pterion, the centre of circle is considered as centre of that pterion. The distance between centre of pterion and following specific external bony landmarks were measured bilaterally by using "Perpendicular Bisector Theorem" [Table/Fig-1]. From the two ends of H shaped suture line, arcs were drawn above and below having radius more than half length of suture bones. Intersecting points of arcs above and below were joined by a scale. The point where this line intersects the H line is taken as centre of the pterion. Standard stainless digital verniers calipers and sliding calipers with an accuracy of 0.1 mm was used. For stellate type of pterion, centre was taken at a point where all the sutures meet. Readings were obtained two times, and then average was computed [12].



[Table/Fig-1]: Depicts the centre of the circle by using "Perpendicular Bisector Theorem".
F: Frontal bone; T: Temporal bone; S: Sphenoid bone; P: Parietal bone

The following measurements were taken. **P-FZ:** The distance from centre of the pterion to the posterolateral aspect of the frontozygomatic (FZ) fissure, The vertical distance from the centre of the pterion to the superior edge of midpoint of zygomatic arch, **P-SS (EAM)**, Distance from the centre of pterion to the anterosuperior margin of external auditory meatus, **P-PM:** distance from the centre of the pterion to the most inferior aspect of the mastoid process, **P-OC:** The distance between centre of pterion and lateral margin of optic canal. The relation between the pterion point and MMA was determined by measuring the distance from the pterion to point nearest to branch of MMA on the internal aspect.

STATISTICAL ANALYSIS

The data was represented in the frequency, percentages and descriptive statistics (mean and standard deviation). The data was analysed using the unpaired t-test. Version 22.0 of Statistical Package for Social Sciences (SPSS) software was employed. The p-value <0.05 is taken as significant statistically. For paired t-test p<0.0001 is significant.

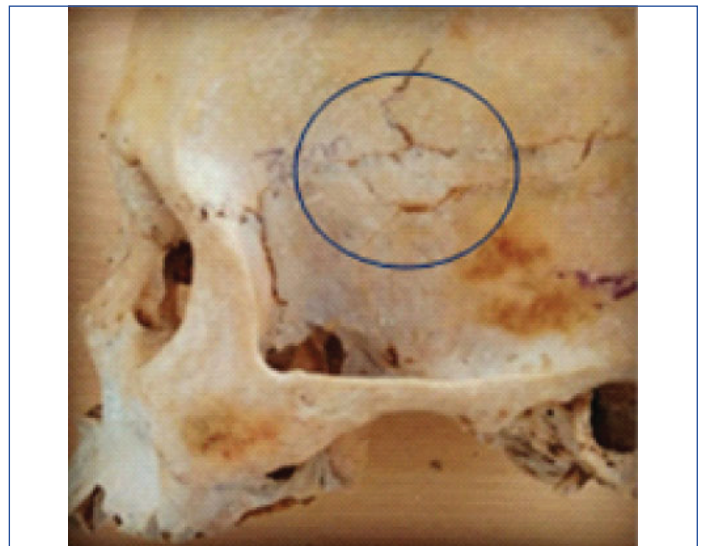
RESULTS

The current study was performed on 100 dried adult skull bones obtained from central Karnataka region. It involved 100 right and 100 left-sided pterions. The commonest type of pterion observed was sphenoparietal 161 (80.5%) followed by epipteric 20 (10%), stellate 10 (5%) and frontotemporal 9 (4.5%) [Table/Fig-2]. One peculiar pterionic formation by two wormian bones in the H-shaped pterion on left-side was observed [Table/Fig-3]. Four normal varieties of pterion were found in present study [Table/Fig-4].

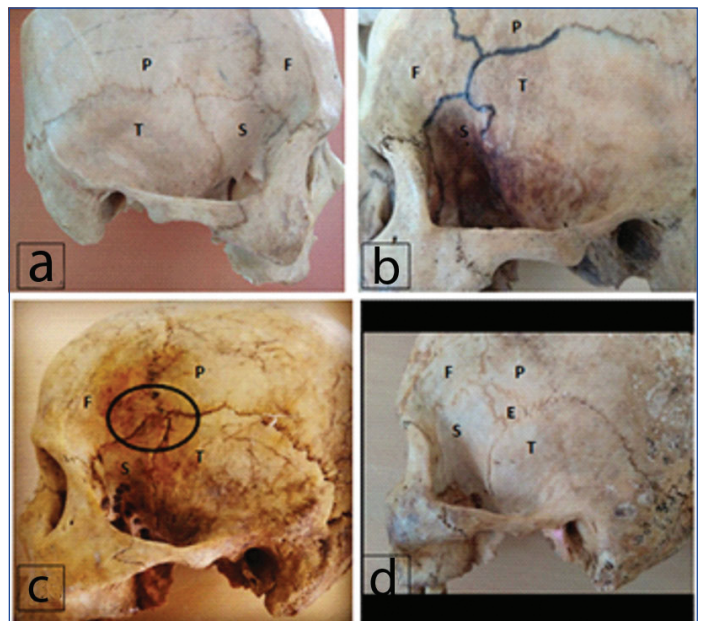
Dimensions recorded from the midpoint of the pterion to different bony landmarks are denoted as mean and standard deviations in [Table/Fig-5]. On the outer aspect of the skull, FZ suture was at a mean distance of 30.48 mm on left and 30.86 mm on right

Type of pterion	Total (n=200) n (%)	Side	
		Left (n=100) n (%)	Right (n=100) n (%)
Sphenoparietal	80.5 (161)	82	79
Frontotemporal	4.5 (9)	4	5
Stellate	5 (10)	5	5
Epipteric	10 (20)	9	11

[Table/Fig-2]: Different types of pterion in adult skull bones.



[Table/Fig-3]: Showing peculiar pterionic formation by two wormian bones in the H-Shaped pterion.



[Table/Fig-4]: Showing types of pterion. a) Sphenoparietal, b) Frontotemporal, c) Stellate, d) EpIPTeric.
F: Frontal bone; T: Temporal bone; S: Sphenoid bone; P: Parietal bone; E: EpIPTeric bone

Landmarks from the pterion	Left-side (n=100)		Right-side (n=100)		t-value	p-value
	Mean	SD	Mean	SD		
P-FZ (in mm)	30.48	3.991	30.86	3.706	-0.698	0.486
P-ZA (in mm)	37.93	3.220	38.68	3.601	-1.553	0.122
P-SS (in mm)	48.37	4.280	48.73	4.997	-0.547	0.585
P-PM (in mm)	78.56	4.338	78.91	4.533	-0.558	0.578
P-OC (in mm)	41.84	2.849	42.23	2.356	-1.056	0.292

[Table/Fig-5]: Linear distance (mm) from the pterion to specific identifiable bony landmarks.
*p-value <0.05 statistical significance; Unpaired t-test

from the centre of the pterion. Mean P-ZA distance was 30.93 mm and 38.68 mm for left and right-side, respectively. Mean distances

measured from the corresponding point of the centre of pterion were 48.37 mm and 48.73 mm to the anterosuperior margin of external auditory meatus on left and right respectively and 78.56 mm on left and 78.91 mm on right is the mean distance from pterion to the most inferior aspect of the mastoid process of the skull.

On the internal aspect of the skull, centre of pterion was 41.84 mm (left) and 42.23 mm (right) away from the lateral margin of the optic canal. Out of 200 pterions studied. In 62% (124) of pterions it was found that anterior division of MMA falls anterior to centre of pterion, 25% (50) coincides with the centre of pterion and remaining 13% (26) the anterior division of MMA was posterior to the pterion. Mean measurement from the centre of pterion to the point nearest to branch of MMA was 2.39 mm on the right-side and 2.19 mm on the left-side of the skull and the difference was statistically significant. ($p < 0.0001$) [Table/Fig-6].

Distance	Left-side (n=100)		Right side (n=100)		t value	p-value
	Mean	SD	Mean	SD		
Pterion to nearest branch of MMA (mm)	2.19	0.7072	2.39	0.20647	9.746	0.0001

[Table/Fig-6]: showing distance of pterion from nearest branch of MMA (mm).
p-value <0.0001 statistical significance, paired t-test

DISCUSSION

Present study was done on samples of 200 pterions from central Karnataka. Study on pterion types and its position in relation to various important structures surrounding it has a lot of clinical significance.

In the present study, various types of pterions were observed sphenoparietal type of pterion was the commonest type which concurs with other studies [Table/Fig-7] [5,6,14-25]. The sphenoparietal type of pterion is common in biped primates it could be the evolutionary basis for its high incidence in humans. In humans separation of anterosuperior portion of the squamous part of temporal bone of lower primates from its original attachment and joining to the greater wing of sphenoid bone at its posteriosuperior angle. In this manner, frontotemporal type of pterion in non human primates changed to the sphenoparietal type of pterion in humans. In primates joining of parietal bone and greater wing of sphenoid is due to morphological changes in neurocranium resulted due to increase in size of brain [13].

In this study, frontotemporal type was least 4.5% which is in agreement with study done on South Indian population [14] but low when compared to Nigerian (Asala SA et al.), Turkish (Oguz O et al.), Kenyan (Mwachaka PM et al.) and Hussain Saheb S et al., studies [15-18]. Occurrence of Stellate type of pterions in the present study

was 5% similar to study done in India by Saxena RC et al., [19]. This result is in contrast to other Indian studies [5,6,18]. Second most common type in the present study was epipteric (10%) in agreement with Korean [20], Thailand [21] Serbian [22] and South Indian [18] studies. Authors also found one peculiar pterionic formation by two wormian bones in the h-shaped pterion on left-side [Table/Fig-3]. Atypical type of pterions (22.85%) were also documented by Priya A and Jain A [23]. Understanding of presence and location of epipteric types of pterion is very vital for neurosurgeons because it can deceive neurosurgeons during burr hole, as the pattern of the pterion might change based on the form, extension, number and location of the epipteric bones [15]. No significant difference was found in the left and right-sided pterions with regards to the shape in the present study as also suggested by Murphy that age, sex and side has no influence on occurrence of the pterion type.

Location of pterion in relation to different bony landmarks P-FZ: The measured length from centre of the pterion to the posterolateral side of the frontozygomatic fissure was 30.48 and 30.86 mm on left and right-side. Other studies reported P-FZ Turkish (3.44 and 3.30 cm) [16], Kenyan (3.82 and 3.88 cm) [17], Nigerian (30.82 and 31.52 mm) [26], Nepalean (3.02 and 3.0 cm) [24], North Indian (3.18 and 3.26 cm) [12] and South Indian (3.23 and 3.32 cm) [27] on left and right-side, respectively.

P-ZA: The perpendicular length from the centre of the pterion to the superior edge of midpoint of zygomatic arch was 37.93 and 38.68 mm on left and right-side, respectively. Previous studies reported P-ZA measurement in Turkish (3.85 and 4.05 cm) [16], Kenyan (3.03 and 3.03 cm) [17], Nigerian (38.77 and 39.1 mm) [26], Nepalean (3.82 and 3.8) [24], North Indian (3.62 and 3.65 cm) [12] and South Indian (3.90 and 4.05 cm) [27] on left and right-side, respectively. Environmental or genetic influence can be basis for these differences.

P-SS (P-EAM): Distance from the centre of pterion to the anterosuperior margin of external auditory meatus was 48.37 and 48.73 mm respectively on left and right-sided pterions. A 5.11 cm and 5.13 cm are the values obtained in North Indian population on left and right-side [12]. A study in Western India showed 56 mm (right) and 54 mm (left) [25]. It was observed that the anterosuperior margin of external auditory meatus corresponded with end of sylvian fissure and posterior ramus of lateral sulcus. This particular value may be of use during operative procedures in area of superior temporal gyrus, sylvian fissure and inferior frontal gyrus. Middle cerebral artery and sylvian veins lie along this fissure and thus help in preventing iatrogenic injuries.

P-PM: Distance from midpoint of the pterion to the most inferior portion of the mastoid process was 78.56 and 78.91 mm on left

Author	Population	Sample size	Spheno parietal	Fronto temporal	Stellate	Epipteric
Murphy T [5] 1956	Australian Aborigenes	388	73	7.50	18.50	1
Asala SA et al., [15] 1996	Nigerian	212	82.1	23.6	-	5.7
Lee UY et al., [20] 2001	Korean	149	76.5	-	-	40.3
Saxena RC et al., [19] 2003	Indian	203	84.72	10.01	5.17	-
Oguz O et al., [16] 2004	Turkish	26	88	10	-	2
Mwachaka PM et al., [17] 2009	Kenyan	79	66	15	7	12
Hussain Saheb S et al., [18] 2011	Indian	125	69.25	17.35	9.70	3.70
Apinhasmit W et al., [21] 2011	Thai	268	81.20	1.10	0.40	17.40
Praba MA et al., [14] 2012	South Indian	50	74	3	9	14
Modasiya UP and Kanani SD [6] 2018	Western Indian	220	80.9	-	10.9	8.18
Desai S and Patel J. [25] 2019	Indian	50	106	2	2	12
Mehta UK et al., [24] 2019	Eastern Nepal	62	80.6	12.9	6.4	-
Knezi N et al., [22] 2020	Serbian	100	87	-	-	13
Priya A and Jain A [23] 2020	North Indian	140	62.85	0	1.42	12.85
Present study 2021	South Indian Karnataka	200	80.5	4.5	5	10

[Table/Fig-7]: Comparison of types of Pterion in different populations in percentage (%) [5,6,14-25].

and right-side in this study which is similar to study done in North India (7.93 left and 7.94 right cm) [12] and Western India (80 mm on both sides) [25].

P-OC: The horizontal gap from the internal side of the midpoint of the pterion to the lateral border of the optic canal. Present study shows 41.84 (left) and 42.23 (right) mm which is in correlation with another South Indian study reported 3.94 and 4.11 cm on left and right-side [27]. There was no significant difference in all these parameters in left and right-sided pterions.

Mean distance from the pterion to the point nearest to branch of MMA was 2.35 mm on the right-side and 2.19 mm on the left-side of the skull. Similar study in south India showed the distance of 0.5 and 0.67 cm in right and left-side [24].

An keyhole approach through the pterion is employed in various operations to remove tumours of the frontal lobe, Broca's area lesions, meningiomas, aneurysms of MMA, extradural hematomas and petroclival tumours. Knowledge about the structures and the distance from pterion to various structure on the internal aspects helps to plan properly and prevent injuries to the arteries or the important structures underneath. Hence, the pterion has gained great importance in neurosurgeries, maxillo-facial surgeries, anthropometry, forensic science, etc.

Limitation(s)

The present study was limited by the fact that it could not study the gender difference between the pterions.

CONCLUSION(S)

The present study concludes that sphenoparietal type of pterion is most common. Second common type was epipteric followed by stellate type. No significant difference was found in type on left and right-side pterions. Location of pterion in relation to different bony landmarks P to FZ, ZA, SS, PM, OC were similar in both sided pterions with no significant difference. Distance from pterion to point nearest to branch of MMA was significantly more on right-side. Further studies comparing different age groups and also different mammals can be undertaken.

REFERENCES

- [1] Moore KL. Clinically orientated Anatomy. 2nd ed. Baltimore: Williams & Wilkins; 1985:796, 798.
- [2] Williams PL, Warwick R, Dyson M, Bannister LH. Gray's Anatomy. 37th ed. New York: Churchill Livingstone; 1989: 352.
- [3] Nayak G, Mohanty BB, Das SR. Morphometric study of pterion and its clinical significance. Asian J Pharm Clin Res. 2017;10(10):142-44.
- [4] Broca, P. Instructions craniologiques et craniométriques. Mém Soc Anthropol Paris. 1875;2:01-203.
- [5] Murphy T. The pterion in the Australian aborigine. Am J Phys Anthropol. 1956;14(2):225-44.
- [6] Modasiya UP, Kanani SD. Study of pterion and asterion in adult human skulls of north Gujarat region. Indian J Clin Anat Physiol. 2018;5(3):353-56.
- [7] Urzi F, Iannello A, Torrioni A, Foti P, Mortellaro NF, Cavallaro M. Morphological variability of pterion in the human skull. Ital J Anat Embryol. 2003;108:83-117.
- [8] Chao SC, Shen CC, Cheng WY. Microsurgical removal of sylvian fissure lipoma with pterion keyhole approach-case report and review of the literature. Surg Neurol. 2008;70(1):S01-90.
- [9] Hyun SJ, Hong SC, Kim JS. Side selection of the pterional approach for superiorly projecting anterior communicating artery aneurysms. J Clin Neurosci. 2010;17:592-96.
- [10] Eaglesham DC. Radiological aspects of intracranial pneumocephalus. Br J Radiol. 1945;18(215):335-37.
- [11] Hussain S, Haseena S, Prasanna LC. Unusual Wormian bones at Pterion- Three case reports. J Biomed Sci and Res. 2010;2(2):116-18.
- [12] Warille AA, Mandloi RS. Measurement of the various identifiable bony landmarks from the centre of pterion in human skulls from Indian Population. Int J Health Sci Res. 2016;6(2):133-37.
- [13] Ashley-Montagu MF. The anthropological significance of the pterion in the Primates. Am J Phys Anthropol. 1933;18:159-336.
- [14] Praba MA, Venkatramaniah. Morphometric study of different types of Pterion and its relation with MMA in dry skulls of Tamil Nadu. J Pharm Biomed Sci. 2012;21(21):01-04.
- [15] Asala SA, Mbajourgu FE. Epigenetic variation in the Nigerian skulls: Sutural pattern at the pterion. East African Med J. 1996;73:484-86.
- [16] Oguz O, Sanli SG, Bozkir MG, Soames RW. The pterion in Turkish male skulls. Surg Radiol Anat. 2004;26:220-24.
- [17] Mwachaka PM, Hassanali J, Odula P. Sutural morphology of the pterion and asterion among adult Kenyans. Braz J Morphol Sci. 2009;26:04-07.
- [18] Hussain Saheb S, Mavishettar GF, Thomas ST, Prasanna LC, Muralidhar P, Magi. A study of sutural morphology of the pterion and asterion among human adult Indian skulls: Biomedical Research. 2011;22(1):73-75.
- [19] Saxena RC, Bilodi AKS, Mane SS, Kumar A. Study of pterion in skulls of awadh area-in and around Lucknow. Kathmandu Univ Med J. 2003;1(1):32-33.
- [20] Lee UY, Park DK, Kwon SO, Paik DJ, Han SH. Morphological analysis of pterion in Korea. Korean J Phys Anthropol. 2001;14(4):281-89.
- [21] Apinhasmit W, Chompoopong S, Chaisuksunt V, Thiraphatthanavong P, Phasukdee N. Anatomical consideration of pterion and its related references in Thai dry skulls for pterional surgical approach. J Med Assoc Thai. 2011;94(2):205-14.
- [22] Knezevic N, Stojic DI, Adic I, Maric D, Pupovac N. Morphology of the pterion in Serbian population. Int J Morphol. 2020;38(4):820-24.
- [23] Priya A, Jain A. Morphological and morphometric study of pterion in adult dry human skulls. Acad Anat Int. 2020;6(2):63-68.
- [24] Mehta UK, Dhakal A, Parajuli SB, Sah SK. Morphometric study of Pterion in dry human skull at Medical College of Eastern Nepal. Journal of Karnali Academy of Health Sciences. 2019;2(3):214-19.
- [25] Desai S, Patel J. Morphometric study of pterion and its clinical significance. Global Journal for Research Analysis. 2019;8(4):289-39.
- [26] Adejuwon SA, Olopade FE, Bolaji M. Study of the location and morphology of the Pterion in adult Nigerian skulls. ISRN Anat. 2013;2013:403937.
- [27] Kalthur SG, Vangara SV, Kiruba L, Dsouza AS, Gupta C. Metrical and non-metrical study of the pterion in South Indian adult dry skulls with notes on its clinical importance. Marmara Medical Journal. 2017;30:30-39.

PARTICULARS OF CONTRIBUTORS:

1. Associate Professor, Department of Anatomy, SSIMS and RC, Davangere, Karnataka, India.
2. Associate Professor, Department of Anatomy, SSIMS and RC, Davangere, Karnataka, India.
3. Professor, Department of Physiology, SSIMS and RC, Davangere, Karnataka, India.
4. Student, Second Year MBBS, SSIMS and RC, Davangere, Karnataka, India.

NAME, ADDRESS, E-MAIL ID OF THE CORRESPONDING AUTHOR:

Dr. Nagraj Mallashetty,
Associate Professor, Department of Anatomy, SSIMS and RC, Jnanashankara,
NH4 Bypass, Davangere-577005, Karnataka, India.
E-mail: nagarajsmalashetti@gmail.com

AUTHOR DECLARATION:

- Financial or Other Competing Interests: None
- Was Ethics Committee Approval obtained for this study? Yes
- Was informed consent obtained from the subjects involved in the study? NA
- For any images presented appropriate consent has been obtained from the subjects. NA

PLAGIARISM CHECKING METHODS: [Jain H et al.]

- Plagiarism X-checker: May 22, 2020
- Manual Googling: Apr 16, 2021
- iThenticate Software: Jul 03, 2021 (20%)

ETYMOLOGY: Author Origin

Date of Submission: **May 21, 2020**
Date of Peer Review: **Jul 06, 2020**
Date of Acceptance: **Apr 17, 2021**
Date of Publishing: **Oct 01, 2021**